



# A Practical MRI Technique for Detecting Abdominal Aorta Aneurysm and Peripheral Arterial Disease

## Abdominal Aorta Anevrizması ve Periferik Arter Hastalığı Tanısında Pratik MR Görüntüleme Tekniği

A Practical MRI Technique for Detecting AAA and PAH

Aykut Recep Aktas<sup>1</sup>, Birsen Unal<sup>2</sup>, Simay Kara<sup>2</sup>, Gokhan Kemal<sup>2</sup>, Omer Yılmaz<sup>1</sup>, Mustafa Kayan<sup>1</sup>, Sevda Yılmaz<sup>2</sup>, Mustafa Kara<sup>1</sup>, Bumin Degirmenci<sup>1</sup>, Meltem Çetin<sup>1</sup>  
<sup>1</sup>Süleyman Demirel University Faculty of Medicine Dept. of Radiology, Isparta, <sup>2</sup>Kırıkkale University Faculty of Medicine Dept. of Radiology, Kırıkkale, Turkey

### Özet

**Giriş:** Anevrizmatik ve aterosklerotik damar patolojilerinde kontrast madde verilmesi sakıncalı olan hastalarda çok kısa süreli koronal Balans Turbo Field Echo (B-TFE) manyetik rezonans (MR) görüntüleme sekansının etkinliğini, kontrastlı MR anjiyografi (MRA) ve konvansiyonel Dijital Çıkarımlı Anjiyografi (DSA) ile karşılaştırmalı olarak değerlendirmek. **Gereç ve Yöntem:** Etik kurul onayı alındıktan sonra, DSA planlanan hastalara inceleme öncesi onamları da alınarak 1,5 Tesla MR (Philips İntera, Netherland) cihazında BTFE görüntüleme yapıldı. Philips DICOM Viewer R2.2 kullanılarak, B-TFE, kontrastlı MRA ve DSA görüntüleri üzerinden, infrarenal aorta, renal arterler, aorta bifurkasyonu, ana, yüzeysel, derin femoral ve iliak arterlerin proksimal kesimlerinden ölçümler alındı. İstatistiksel analiz için SPSS 11.5 programı kullanılmıştır. B-TFE, MRA ve DSA tekniklerinin birbirleri yerine kullanılabilirlik ve güvenilirliklerinin saptanması için sınıf-içi korelasyon katsayısı ve güvenilirlik değerleri, iki yöntemle ölçülen değerler arasında farklılığı incelemek için de bağımlı gruplarda t-testi uygulandı. **Bulgular:** Aorta, iliak ve femoral arterlerde B-TFE sekans ölçümleri ile MRA ve DSA ölçümleri arasında yüksek korelasyon mevcuttu. Ancak renal ve popliteal arterlerde B-TFE ölçümleri, DSA ve MRA kadar güvenilir bulunmadı. **Tartışma:** Periferik arter hastalığının tanısında, DSA altın standart görüntüleme yöntemi olmakla birlikte işlem esnasında kontrast madde ve X-ışını kullanılır. DSA'da tespit edilen aorta, iliak ve femoral arterlerdeki anevrizmatik ve aterosklerotik patolojilerin takibinde ve kontrast madde verilmesi sakıncalı olan hastalarda koronal B-TFE sekansı güvenle kullanılabilir.

### Anahtar Kelimeler

MRİ; Anjiyografi; Dijital Çıkarım; Periferik Arter Hastalığı; Anevrizma

### Abstract

**Aim:** Peripheral Arterial Disease(PAD) and abdominal aorta aneurysm(AAA) are frequent problems in geriatric population. In DSA, CTA or MRA techniques contrast agents has to be used for diagnosis that can be nephrotoxic for elderly patients. Magnetic resonans imaging (MRI) is the most powerful, non-ionising radiological diagnostic tool that has the highest soft tissue contrast resolution. The aim of our study was to investigate the effectivity of MRI by the means of detecting the AAA and PAD in comparison with DSA. **Material and Method:** After getting ethical committee approval and informed consent, we have performed Balanced turbo field echo(B-TFE) MRI technique without contrast agent in 1.5 Tesla MRI device before DSA examination. The luminal diameters of renal arteries, infrarenal abdominal aorta, iliac and femoral arteries was measured by using Philips DICOM Viewer R2.2 application. The intraclass correlation coefficient and reliability used to check if the techniques could be used for each other and the t-test was used to measure the differences between them. **Results:** There has been a high relationship between B-TFE and DSA in detecting the pathologies of larger arteries like aorta. In the case of small arterial pathologies, there is relatively lower relationship between BTFE and DSA. **Discussion:** For the diagnosis of AAA and PAD, DSA is the gold standart technique but it is invasive and patients have radiation exposure. In the follow up of geriatric patients with larger arterial pathologies B-TFE can be used instead of contrast enhanced MRA and invasive DSA.

### Keywords

MRİ; Angiography; Digital Subtraction; Peripheral Arterial Disease; Aneurysm

DOI: 10.4328/JCAM.2725

Received: 14.08.2014 Accepted: 01.09.2014 Printed: 01.05.2016 J Clin Anal Med 2016;7(3): 295-9

Corresponding Author: Aykut Recep Aktas, Department of Interventional Radiology, Medical Faculty, Suleyman Demirel University, Isparta, Turkey.

T.: +90 2462112050 F.: +90 2462112050 GSM: +905324747281 E-Mail: aykutraktas@gmail.com

## Introduction

Abdominal Aorta Aneurism (AAA) and Peripheral Artery Disease (PAD) are widespread diseases especially in elderly patients. Digital subtraction angiography (DSA), is widely accepted as gold standard method for evaluation of abdominal, iliac and peripheral arteries. Magnetic resonance imaging (MRI), is the radiological diagnostic method that has highest soft-tissue contrast resolution while having no ionizing radiation. DSA is an invasive procedure and sometimes contrast agents have hazardous effects on the kidneys. Three dimensional magnetic resonance angiography (3DMRA) development has emerged as a non-invasive technique. MRA has the advantages while having no X-ray exposure and arteries can be studied in three dimensions and excellent soft tissue contrast can be provided. DSA in the front-rear projection, in the assessment of stenosis is sometimes inadequate because of superposition. This can cause treatment planning mistakes. In addition to DSA and MRA, coronal Balanced-Turbo Field Echo (B-TFE) was used as a fast and non contrast enhanced sequence. This technique have different names under different brands. B-TFE (Balanced Turbo Field Echo-Philips), FIESTA (Fast Imaging Employing Steady State Acquisition-GE), True FISP (True Fast Imaging with Steady State Precession-Siemens). In SSFP, RF signals are applied to the body in very short time intervals that has a great SNR independent from the blood stream and excellent blood-tissue contrast ( $T2^* / T1$ ) was obtained. With a shorter examination time SSFP has allowed us to examine patient without breath holding. Today, this sequence is being used in cardiac examinations(1,2).

## Material and Method

The diagnosis of peripheral vascular disease was investigated with MRI (1.5T, Philips Medical Systems, Netherlands) as coronal B-TFE and three dimensional contrast enhanced MRA prior to digital subtraction angiography (DSA) (Allura, Philips Medical Systems, Netherland).

We studied the differences between examinations without gender and age discrimination, and correlations between different sequences, were evaluated statistically using SPSS program.

This study was approved by the institutional review board of our university hospital. Written informed consent was obtained from all patients.

### Imaging parameters

#### Magnetic resonance imaging

MRI was performed using sense body coil and the localization sequences were taken from aorta, iliac and femoral arteries in three plans.

Getting started with examination first coronal B-TFE sequence of 40 sections with a total of 24 seconds, matrix 192x256, flip angle 80 °, FOV 430 mm, slice thickness 4mm, gap 2 mm, TR 3.5 ms and TE 1.7 ms which is a Steady State Free Precession (SSFP) technique.

Before MRA sequences has been taken 2D TIMING (TR 13.7 ms, TE 2 ms, 128x128 Matrix, 450 FOV, 10 mm slice thickness) sequence were performed by 2ml of contrast agent and inspecting the arrival time at the level of pre-aortic bifurcation was detected. Contrast agent dose and injection rate; was calculated according to the duration of 2D TIMING sequence and patient's

weight. 20 ml of 0.9% saline was injected after the contrast material in all examinations.

MRA sequences which has matrix 512x512, slice thickness 3 mm, flip angle 40 °, TR 5.1 ms, TE of 1.5 ms was launched with the raw data and reconstruction time lasted about 60 seconds. 3DMRA images were obtained in the 9-20 plan with the help of multiplanar intensity projection (MIP) software.

#### Digital Subtraction Angiography

The dynamic peripheral vascular examination protocol was used for each patient.

The active ingredient N, N'-bis (2,3-dihidroksipropil) -5 [(hidroksiasetil) methylamino] -2,4,6-triiodo-1 ,3-benzendicarboxamide (Iomeprol) was used as contrast agent.

5F intraducer sheath is inserted in to right or left common femoral artery with the use of Seldinger technique. Pigtail catheter was advanced in the vessel lumen to the level to be viewed through the suprarenal aorta.

DSA device was connected to and synchronized working automatic injector (MEDRAD Inc, Warrendale, PA) and injection of contrast medium through the pigtail catheter at the level of renal arteries was performed. By the way renal arteries, distal segment of abdominal aorta, aortic and iliac bifurcations, iliac and femoral arteries were examined.

#### Image assessment

Philips DICOM Viewer R2.2 was used to ases the DICOM images of B-TFE, MRA, 3DMRA sequences and DSA. The arterial tree was divided into 16 segments as the right and left renal arteries, infrarenal aorta, aortic bifurcation, iliac bifurcation, right and left main iliac artery, right and left external and internal iliac artery, right and left common superficial and deep femoral artery. Total of 704 diameter measurements were made in 11 patients and 44 sequences.

#### Statistical Analysis

Data analysis was made using SPSS 11.5 (Chicago, IL) package program. Our goal is to evaluate the similarity between sequences. The intraclass correlation coefficient was used to compare the values obtained in measurements and reliability used to check if the techniques could be used for each other , the t-test was used to measure the differences between them.

## Results

11 out of 13 patients agreed to participate in the study. Patients were between 48-69 years old and the average was 57 years. 1 (9%) patient was female, 10 (91%) patients were male. Vessel diameters from each diagnostic method compared with B-TFE sequence; intra-class correlation coefficient has been calculated statistically (Table 1). We found any correlation in unit measurements of vessel diameters between, B-TFE (Figure 1a), MRA (Figure 1b) 3DMRA (Figure 1c) and DSA(Figure 1d). This compare values presented at Table 2.

We found that in most large vessel diameter measurements, B-TFE has a perfect harmony with the MRA, 3DMRA and DSA. But in small vessels, B-TFE has a moderate correlation with MRA and 3DMRA and low correlation with DSA diameter measurements.

Table 1. Measurements of the diameter of the arterial segments in BTFE, MRA, 3DMRA sequences and DSA

Hasta No	Seg. No	Arterial segments	B-TFE			MRA			3DMRA			DSA		
			A1	B1	C1	A2	B2	C2	A3	B3	C3	A4	B4	C4
1	1	INFRARENAL AORTA DIAMETER	9.8	1	2.97	23.8	1	2.38	24	1	2.7	88.3	1	2.93
	2	R RENAL ARTERY DIAMETER	2.5	0.26	0.76	5.5	0.23	0.55	5.5	0.23	0.62	20.5	0.23	0.68
	3	L RENAL ARTERY DIAMETER	3	0.31	0.91	6.9	0.29	0.69	6.7	0.28	0.75	28.5	0.32	0.95
	4	BIFURCATION DIAMETER	10.5	1.07	3.18	22.4	0.94	2.24	23.3	0.97	2.62	85.1	0.96	2.83
	5	R COMMON ILIAC A.	5.8	0.59	1.76	13.1	0.55	1.31	13.3	0.55	1.49	51.4	0.58	1.71
	6	R EXTERNAL ILIAC A.	4.2	0.43	1.27	8.2	0.34	0.82	8.7	0.36	0.98	39.1	0.44	1.3
	7	R INTERNAL ILIAC A.	3.3	0.34	1	8.9	0.37	0.89	8.2	0.34	0.92	35.8	0.41	1.19
	8	L COMMON ILIAC A.	5.4	0.55	1.64	13.9	0.58	1.39	14.6	0.61	1.64	59.6	0.67	1.98
	9	L EXTERNAL ILIAC A.	4.1	0.42	1.24	10.6	0.45	1.06	9.4	0.39	1.06	38	0.43	1.26
	10	L INTERNAL ILIAC A.	3	0.31	0.91	9.2	0.39	0.92	9.4	0.39	1.06	37.7	0.43	1.25
	11	R COMMON FEMORAL A.	4.1	0.42	1.24	12.2	0.51	1.22	13.8	0.58	1.55	40.5	0.46	1.35
	12	R SUPERFICIAL FA.	4.4	0.45	1.33	10.7	0.45	1.07	9.7	0.4	1.09	34.1	0.39	1.13
	13	R DEEP FEMORAL A.	2.3	0.23	0.7	6	0.25	0.6	4.6	0.19	0.52	26.6	0.3	0.88
	14	L COMMON FEMORAL A.	4.4	0.45	1.33	12.3	0.52	1.23	13.8	0.58	1.55	40.2	0.46	1.34
	15	L SUPERFICIAL FA.	4.2	0.43	1.27	10.8	0.45	1.08	10.2	0.43	1.15	35.7	0.4	1.19
	16	L DEEP FEMORAL A.	3.3	0.34	1	10	0.42	1	8.9	0.37	1	30.1	0.34	1

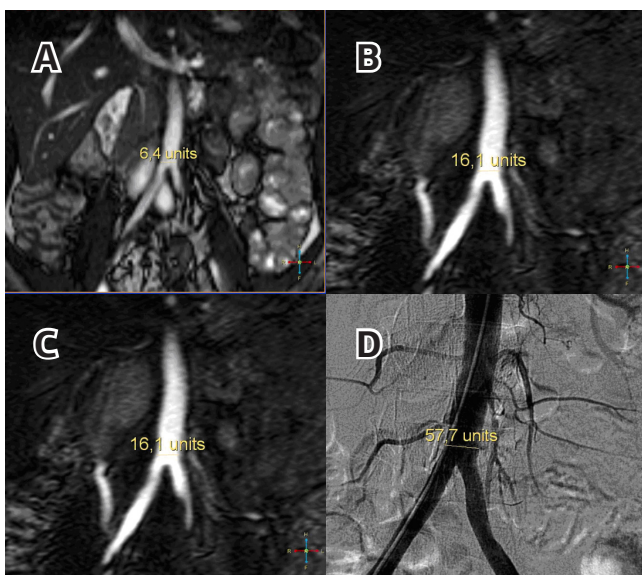


Figure 1. Transvers diameter measurement 1 cm above aortic bifurcation from coronal section. B-TFE sequence(A), MRA sequence(B), 3DMRA sequence(C), DSA image(D).

Table 2. Comparison of sequences

	Interclass Corelation Coefficient (ICC)
A_B-TFE & A_MRA	0,3946
B_B-TFE & B_MRA	0,8861
C_B-TFE & C_MRA	0,7517
A_B-TFE & A_3DMRA	0,4769
B_B-TFE & B_3DMRA	0,8776
C_B-TFE & C_3DMRA	0,7222
A_B-TFE & A_DSA	-0,6796
B_B-TFE & B_DSA	0,8618
C_B-TFE & C_DSA	0,6808

Another means B-TFE could be as reliable as MRA, and DSA in large vessels like aorta, iliac, femoral arteries. But this is not the case for small arteries like renal arteries.

Also difference between measurements of B-TFE and DSA was

examined by t-test' 'on dependent groups and no significant difference was found( $p > 0.05$ ). Details summarized on Table 3.

**Discussion**

Today, AAA rupture and PAD increase the morbidity and mortality in many healthcare facilities among the world. Approach to this issue, as in every disease is to provide, early screening methods before the illness has emerged and is to use minimally invasive and easy methods for diagnosis (3). In addition to conventional surgical procedures endovascular minimally invasive attempts are also considered for treatment (4).

When evaluating vascular disease, there are some basic rules in the selection of methods. Because there are many methods and many applications in the diagnosis of a disease. In this approach some criteria as utility, harmlessness, the economy are considered. The most important point in selection of the method is that has the most accurate results. Diagnostic activity is the basic criteria in determining the value of a radiological diagnostic method. It is required to compare with a standard, to evaluate the value of any diagnostic examination. This standard reference method based analysis is called "gold standard".

Benefit of non-invasive test is that it can be used as a screening test for arterial disease, and the treatment can be performed in a short time before the progress of pathology. Another benefit is the power of saving time and money in the intensive clinical work (5).

Today MRA, pushing the limits and approaching to DSA which is considered as the gold standard.

In the diagnosis of AAA and PAD contrast-enhanced MRA and BTA is a quite commonly used methods alternative to DSA technique. Prince et al. revealed benefits of using contrast in MRA, in 1995 (6). MRA is the primary technique for the detection of AAA and PAD in some centers. MRA became widely available after rapid development of technology and widespread use of gadolinium contrast agents (7).

Although the most basic component of the MRA was the use of contrast media, many centers use the contrast-free protocols.

Table 3. P value

		Mean	Std. Deviation	t	df	P value Sig (2-tailed)
Pair 1	A_B-TFE - A_DSA	-28,521	23,1011	-16,379	175	,000
Pair 2	B_B-TFE - B_DSA	,07632	,189898	5,332	175	,000
Pair 3	C_B-TFE - C_DSA	,01704	1,142864	,198	175	,843
Pair 4	A_MRA - A_3DMRA	,548	1,8994	3,830	175	,000
Pair 5	B_MRA - B_3DMRA	,01560	,110567	1,872	175	,063
Pair 6	C_MRA - C_3DMRA	-,31188	1,167712	-3,543	175	,001
Pair 7	A_DSA - A_CINEAN	15,375	16,5186	12,348	175	,000
Pair 8	B_DSA - B_CINEAN	-,00296	,091574	-,428	175	,669
Pair 9	C_DSA - C_CINEAN	,03058	,427721	,948	175	,344
Pair 10	A_MRA - A_DSA	-23,660	21,2524	-14,770	175	,000
Pair 11	B_MRA - B_DSA	,04001	,142990	3,712	175	,000
Pair 12	C_MRA - C_DSA	,04981	1,878216	,352	175	,725
Pair 13	A_3DMRA - A_DSA	-24,209	21,1148	-15,210	175	,000
Pair 14	B_3DMRA - B_DSA	,02441	,115147	2,812	175	,005
Pair 15	C_3DMRA - C_DSA	,36170	1,872108	2,563	175	,011

In the diagnosis of vascular disease, spatial resolution, image acquisition speed, and functional evaluation is important and research is increasing at this level (8).

In AAA and PAD the role of angiography has changed in recent years. Rather angiography corresponds to a diagnostic method, is not a primary diagnostic method for PAD. If the intervention is planned to a lesion of PAD catheter angiography is the gold standard method, and treatment is planned according to the angiography data. According to many researchers angiography assess suitability of the lesion for endovascular treatment or surgery (8, 9).

MRA is an ideal imaging method that can be done without the need to ionizing radiation in many anatomic region, including large body parts.

Intravascular contrast agent increases sensitivity of MRA while having no flow artifacts and saturation effects. Also there are lots of contrast-free protocols available. The first one is Black Blood technique which allows examination of intramural hematoma and wall anatomy in dissection perfectly. Another two-dimensional technique is time of flight (TOF) analysis that is used as support after contrast enhanced technique affected by venous filling under the knee (10,11). These are relatively long lasting techniques then B-TFE.

B-TFE sequence was investigated to assess the degree of stenosis and obstruction in the lumen of abdominal aorta, renal arteries, iliac and femoral arteries, comparing with the MRA techniques and the gold standard DSA.

There was a high correlation for larger vessel diameters between B-TFE, MRA and DSA.

When small vessel diameter measurements in B-TFE were evaluated, there is a high compliance with MRA and moderate compliance with DSA. It was accepted that there were lesion if when 50% lumen stenosis present. As Loewe et al. many researchers, had used a rough ranking by giving a range such as grade 1 (0-29% open), grade 2 (30-69%, hemodynamic no meaning), grade 3 (70-99%, hemodynamically significant); grade 4 (fully occluded) and sensitivity, specificity values were calculated (12). In our study, we prefer more precise measure-

ments like vessel diameters to obtain more accurate results. All the arterial tree can be displayed by the examination of the multi-station but also needs to be done with multiple contrast agent injection. The duration of the examination time of the patient's has passed by to set their position and contrast injection. An disadvantage of multi-contrast application is the increase of signal of surrounding soft tissue, so CNR is reduced and a moving table technique may reduce the amount of noise(13).

There are resources stating that MRA was as a highly reliable screening method in evaluation of peripheral arteries (14). Also some studies has shown that MRA 's sensitivity and specificity was close to DSA (15).

Interventional treatment's success has increased by knowing the origin of stenosis in the femoral or iliac artery and associated complications has decreased (16). Therefore, B-TFE can provide trust to physicians by knowing the state of the arterial lumen in claudicating patients before intervention. MRA technique can protect the patients from potential complications and if necessary can provide attempt scrolling to the contralateral femoral or radial artery(17).

We consider B-TFE sequence to be a practical method for the vascular studies; B-TFE can be as valuable as MRA and DSA in aortic dissection, thrombosis, embolism or AVM malformation. It can also be useful for cardiac and renal failure patients who has contrast material and machining intolerance. B-TFE can be taken into routine clinical use and may increase the performance.

It has been reported that in some clinics MRA has done before interventional treatment (17).

In our study, we examined beginning from renal arteries through the abdominal aorta, iliac and femoral arteries and by using the same coil more distally through popliteal artery, tibial and peroneal arteries. B-TFE has the limiting condition as with MRA such as susceptibility artefacts and effectivity may decrease in small and distal arteries. But average duration of angiography techniques such as contrast used TOF MRA and DSA is about 10 minutes while in B-TFE this time does not exceed 20-30 seconds.

In conclusion, B-TFE is a fast and reliable method and provide high-blood-tissue contrast which clearly evaluate the vessel lumen and the vessel wall of the great vessels. A large renal artery or abdominal aorta occlusion can be diagnosed easily in MRI device in a very short time without contrast injection. This study confirmed that B-TFE is highly secure and non-invasive technique for follow-up which can be used instead of MRA and DSA in elderly patients to reduce complications.

### Competing interests

The authors declare that they have no competing interests.

### References

1. Scheffler K, Lehnhardt S. Principles and applications of balanced SSFP techniques. *Eur Radiol* 2003;13(11):2409-18.
2. Markl M, Alley MT, Pelc NJ. Balanced phase-contrast steady-state free precession (PC-SSFP): a novel technique for velocity encoding by gradient inversion. *Magn Reson Med* 2003;49(5):945-52.
3. Schoenberg SO, Rieger J, Nittka M, Dietrich O, Johannson LO, Reiser MF. Renal MR angiography: current debates and developments in imaging of renal artery stenosis. *Semin Ultrasound CT MR* 2003;24(4):255-67.
4. Chantelau E, Lee KM, Jungblut R. Association of below-knee atherosclerosis to

- medial arterial calcification in diabetes mellitus. *Diabetes Res Clin Pract* 1995; 29(3):169-72.
5. Prince MR, Chabra SG, Watts R, Chen CZ, Winchester PA, Khilnani NM et al. Contrast material travel times in patients undergoing peripheral MR angiography. *Radiology* 2002;224(1):55-61.
  6. Mozes G, Keresztury G, Kadar A, Magyar J, Sipos B, Dzsinih S et al. Atherosclerosis in amputated legs of patients with and without diabetes mellitus. *Int Angiol* 1998;17(4):282-6.
  7. Barretto S, Balhnan KV, Rooke TW, Kullo IJ. Early-onset peripheral arterial occlusive disease: clinical features and determinants of disease severity and location. *Vasc Med* 2003;8(2):95-100.
  8. Prince MR, Grist TM, Debatin JF. *3D Contrast MR Angiography*, 3rd Ed. New York: Springer-Verlag; 2003. p.729-34.
  9. Du J, Carroll TJ, Block WF, Fain SB, Korosec FR, Grist TM, et al. SNR improvement for multiinjection time resolved high-resolution CE-MRA of the peripheral vasculature. *Magn Reson Med* 2003;49(5):909-17.
  10. Maki JH, Prince MR, Chenevert TC. Optimizing three-dimensional gadolinium-enhanced magnetic resonance angiography. Original investigation. *Invest Radiol* 1998;33(9):528-37.
  11. Prakken NH, Vonken EJ, Velthuis BK, Doevendans PA, Cramer MJ. 3D MR coronary angiography: optimization of the technique and preliminary results. *Int J Cardiovasc Imaging* 2006;22(3-4):477-87.
  12. Loewe C, Schoder M, Rand T, Hoffmann U, Sailer J, Kos T et al. Peripheral Vascular Occlusive Disease: Evaluation with Contrast-Enhanced Moving-Bed MR Angiography Versus Digital Subtraction Angiography in 106 Patients *AJR* 2002;179(4):1129-33.
  13. Hany TF, Carroll TJ, Omary RA, Esparza-Coss E, Korosec FR, Mistretta CA et al. Aorta and runoff vessels: single injection MR angiography with automated table movement compared with multi-injection time-resolved MR angiography-initial results. *Radiology* 2001;221(1):266-72.
  14. Visser K, Hunink MG. Peripheral arterial disease: gadolinium-enhanced MR angiography versus color-guided duplex US a meta-analysis. *Radiology* 2000;216(1):67-77.
  15. Rofsky NM, Johnson G, Ademan MA, Rosen RJ, Krinsky GA, Weinreb JC. Peripheral vascular disease evaluated with reduced-dose gadolinium enhanced MR angiography. *Radiology* 1997;205(1):163-9.
  16. Wang Y, Winchester PA, Khilnani NM. Contrast-enhanced peripheral MR angiography from the abdominal aorta to the pedal arteries: combined dynamic two-dimensional and bolus-chase three-dimensional acquisitions. *Invest Radiol* 2001;36(3):170-7.
  17. Winterer JT, Laubenberger J, Scheffler K, Neumann K, Bayraktarli YR, Allmann KH et al. Contrast-enhanced subtraction MR angiography in occlusive disease of the pelvic and lower limb arteries: results of a prospective intraindividual comparative study with digital subtraction angiography in 76 patients. *J Comput Assist Tomogr* 1999;23(4):583-9.

**How to cite this article:**

Aktas AR, Unal B, Kara S, Kemal G, Yilmaz O, Kayan M, Kara M, Degirmenci B, Çetin M. A Practical MRI Technique for Detecting Abdominal Aorta Aneurysm and Peripheral Arterial Disease. *J Clin Anal Med* 2016;7(3): 295-9.